

Protective Effect of *Punica granatum* on Ferric Nitrilotriacetate-Induced Toxicity in *Oreochromis niloticus*

Piya KOSAI¹, Wipaphorn JAIKUA¹, Kanitta JIRAUNGKOORSKUL² and Wannee JIRAUNGKOORSKUL^{1,*}

¹Department of Pathobiology, Faculty of Science, Mahidol University, Bangkok 10400, Thailand

²Department of Occupational Health and Safety, Faculty of Public Health, Mahidol University, Bangkok 10400, Thailand

(* Corresponding author; e-mail: wannee.jir@mahidol.ac.th)

Received: 14 June 2014, Revised: 3 January 2015, Accepted: 4 February 2015

Abstract

This study evaluates the efficiency of a dietary supplement of *Punica granatum* in reducing the toxicity of ferric nitrilotriacetate in *Oreochromis niloticus*, with emphasis on histopathological analysis. Fish were given a dietary supplement in doses of 0 (groups 1 and 2) and 60 mg g⁻¹ of *P. granatum* (groups 3 and 4) for 28 days. After a time, fish in groups 2 and 4 received intraperitoneal injections of 9 mg kg⁻¹ of ferric nitrilotriacetate. 24 hours after injection, histopathological lesions for example, lifting and hyperplasia of the gills, edema, and some areas of necrosis in the hepatocytes, were observed in group 2. Hemosiderin and renal tubular necrosis were also seen. There was degeneration and necrosis of the longitudinal folds in the intestine. Goblet cells showed hyperplasia and also hypertrophy. Fish that received pre-treatment in group 4 showed only slight alterations when compared to those of group 2. The results suggest that the dietary supplement helps reduce the histopathological alteration of ferric nitrilotriacetate toxicity in fish.

Keywords: Fish, herb, pomegranate, histopathology, Tilapia, *Oreochromis niloticus*

Introduction

Nowadays, people are increasingly becoming aware of the importance of keeping healthy and the positive effects of ingesting natural products, especially from plants. Thailand uses immunostimulant plants in “Thai Traditional Medicine”, which can be used to treat human and animal diseases. *Punica granatum* (PG or “TubTim” in Thai), commonly known as pomegranate, is a large shrub or small tree belonging to the Punicaceae family. The literature reveals that pomegranate exhibits therapeutic uses i.e., antibacterial [1,2], antifungal [3,4], anthelmintic [5,6], antifertility [7], antioxidant [8,9], antidiabetic [10,11], and anticancer [12] properties. The principal constituents of the pomegranate are apigenin, ellagic acid, tannin, puniceic acid, anthocyanidin, flavonoid, and flavone [13,14]. In recent years the use of immunostimulants as dietary supplements to enhance fish health and reduce chemical toxicity has been increasing [15,16].

Nitrilotriacetic acid is an aminotricarboxylic acid chelating agent, which forms water-soluble chelate complexes with several metal cations such as Ca²⁺, Cu²⁺ or Fe³⁺. Because of its ability to chelate calcium and magnesium ions, trisodium salt is used in laundry detergents to replace phosphates, the use of which has been restricted by legislation in some countries owing to their contribution to the eutrophication of lakes and ponds [17]. Oakes *et al.* [18] investigated the relationship between oxidative stress and reproductive dysfunction in wild white sucker (*Catostomus commerson*) with short-term exposure to pulp-mill effluent, and also reported that *in vivo* administration of ferric nitrilotriacetate (Fe-NTA) significantly reduced circulating sex steroids. Awai *et al.* [19] reported glycosuria and hepatic

parenchymal iron deposits in rats following intraperitoneal injections with ferric nitrilotriacetate. These changes were similar to those characteristics of iron-overload seen in idiopathic hemochromatosis. Additionally, it induces acute nephrotoxicity [20,21] and hepatotoxicity [22,23] caused by the elevation of free serum iron concentration, following its reduction at the luminal side of the proximal tubule [24], generating reactive oxygen species, leading to lipid peroxidation and inducing oxidative stress in the liver [25].

The search for a new dietary supplement is mainly prompted by the great development of fish farming, and the stress situations and disease which arise from intensive culture aquaculture. With this aim, the present study was performed to investigate the efficiency of a dietary supplement of *Punica granatum* in reducing the toxicity of ferric nitrilotriacetate in *Oreochromis niloticus* via histopathological analysis.

Materials and methods

Animal

Oreochromis niloticus, 18.20±0.25 g body weight and 10.58±0.78 cm total length, were purchased from a commercial hatchery in Bangkok, Thailand. Tap water was filtered with activated charcoal to eliminate chemical contamination. The physicochemical characteristics of water were measured daily, according to the experimental procedures described in *Standard Methods for the Examination of Water and Wastewater* [26]. Under laboratory conditions, fish were acclimated for 30 days at 29.0±1.0 °C, pH 6.6 - 7.0, total hardness 68 - 80 mg L⁻¹ (as CaCO₃), alkalinity 75 - 80 mg L⁻¹, and conductivity 190 - 220 µmhos cm⁻¹. A 16:8 h light-dark cycle was maintained throughout. Chlorine residual and ammonia were below detection limits. Fish were fed twice a day with 37 %-protein commercial fish food. The quantity of food was 2 % of the initial body weight per day. The animal care and handling in this research was performed following the instruction of the Mahidol University-Institutional Animal Care and Use Committee. Therefore, this research followed the mammal animal care and use guidelines, i.e.: (1) Use, care and transportation of fish for toxicopathological testing complied with all applicable animal welfare laws. (2) The number of fish was kept to the minimum requirement required to achieve scientifically valid results. (3) All protocols were taken to avoid discomfort, distress, or pain in the fish. (4) The appropriate dosage of the anesthesia was 200 mg L⁻¹ ethyl-3-aminobenzoate methanesulfonate salt, and the euthanasia dosage took the form of an overdose of this chemical.

Preparation of dry leaf with fish food

Punica granatum (PG) was collected from a local area in Nakorn Pathom Province, Thailand. Fresh leaves were washed several times in water, dried in an incubator at 45 °C for 72 h, and made into a semi powder by crushing using a mortar and pestle. The extraction was done by following the method of Winkaler *et al.* [27] with minor modification. Briefly, fish food was ground in a blender and hydrated with 0.7 mL g⁻¹ distilled water, mixed with the leaf semi powder extract, and extruded through a minced-meat processing machine. Later, the mixture was broken into small pellets by hand and dried at 60 °C in a hot air oven for 48 h. The fish were fed twice a day with the prepared dry leaf food supplementation for 28 days.

Preparation of ferric nitrilotriacetate solution

A solution of ferric nitrilotriacetate (Fe-NTA) was prepared by following the method of Awai *et al.* [19]. Briefly, ferric nitrate (0.16 mmol kg⁻¹ body weight) solution was mixed with a 4-fold molar excess of disodium salt of NTA (0.64 mmol kg⁻¹ body weight), and the pH adjusted to 7.4 with a sodium bicarbonate solution. The solution was prepared immediately before use.

Experimental design

The fish (n = 40) were randomly divided into 4 groups. Each fish was transferred to each aquarium as per the following: group 1 (G1) and group 2 (G2) were given normal fish food; group 3 (G3) and group 4 (G4) were given 60 mg g⁻¹ *P. granatum* (PG). After 28 days, the fish in G2 and G4 were

intraperitoneally injected with 9 mg kg⁻¹ Fe-NTA, given in a volume of 10 ml kg⁻¹ body weight. 24 h after injection, the gill, liver, kidney and intestines were removed from each group.

Specimen preparation for histopathological study

The procedures used for light microscopy were modified from Humason's method [28]. Briefly, the tissues were fixed in the 10 % buffered formaldehyde for 24 h, dehydrated through a graded series of ethanol, and cleared with xylene solutions. All tissue specimens were embedded in a block using melted paraffin at the embedding station. The paraffin blocks were sectioned at 4 - 5 µm thickness using a rotary microtome, and stained with hematoxylin and eosin. The stained slides were examined to evaluate histopathological changes by using a Nikon E600 light microscope, and photographed by using a Nikon DXM 1200 digital camera (Tokyo, Japan).

Histopathological evaluation

Histopathological alterations were evaluated semiquantitatively by ranking tissue lesion severity. Ranking was indicated from – to + + +, depending on the degree and extent of the alteration, as follows: (-) no pathological alterations; (+) mild; (+ +) moderate and (+ + +) severe pathological alterations. This ranking was used by Schwaiger *et al.* [29] to establish an overall assessment value of the histopathological lesion for each individual fish tissue. Ten slides were observed from each organ and treatment.

Results

Gills

Control group: The primary lamellar was the row of long thin filaments, which projected from the arch like the teeth of a comb. The surface area of the gills was increased further by the formation of regular semilunar folds across the dorsal and ventral surface, the secondary lamellar. The primary lamellar epithelium was a few layers thick. Each secondary lamellar was made up of 2 sheets of epithelium, delimited by many pillar cells, which were contractile and separated the capillary channels. One to two erythrocytes were usually observed within each capillary lumen. No recognizable changes were observed in the gills of G1 and G3 throughout this experiment (**Figures 1a, 1c**).

Treated groups: The present study revealed several lesions of gill tissue in the Fe-NTA treatment group (G2), including bending of the distal secondary lamellae, a lifting of the outer layer of the lamellar epithelium, the deformation of cartilage and, finally, hyperplasia in the primary epithelial cells. Eventually, the whole epithelium sloughed off, and the lamella lost its rigidity. The PG feeding group (G4) showed similar but less severe alterations than those of G2 (**Figures 1b, 1d**). The semiquantitative scoring of gill lesions is shown in **Table 1**.

Liver

Control group: The liver histology of G1 and G3 revealed a typical parenchymatous appearance. At the light microscopic level, the liver was divided into irregularly shaped lobules, separated by the hepatopancreas and bile duct. The hepatocytes were polygonal and had distinct central nuclei with densely staining chromatin margins and prominent nucleoli (**Figures 2a, 2c**).

Treated groups: The hepatocytes in G2 began to swell, and their vacuolization was observed. They showed congestion and exhibited increasing size and pyknotic nuclei in some areas. The hepatocytes in G4 showed similar alteration patterns as those of G2, but the conditions were less severe (**Figures 2b, 2d**). The semiquantitative scoring of liver lesions is shown in **Table 2**.

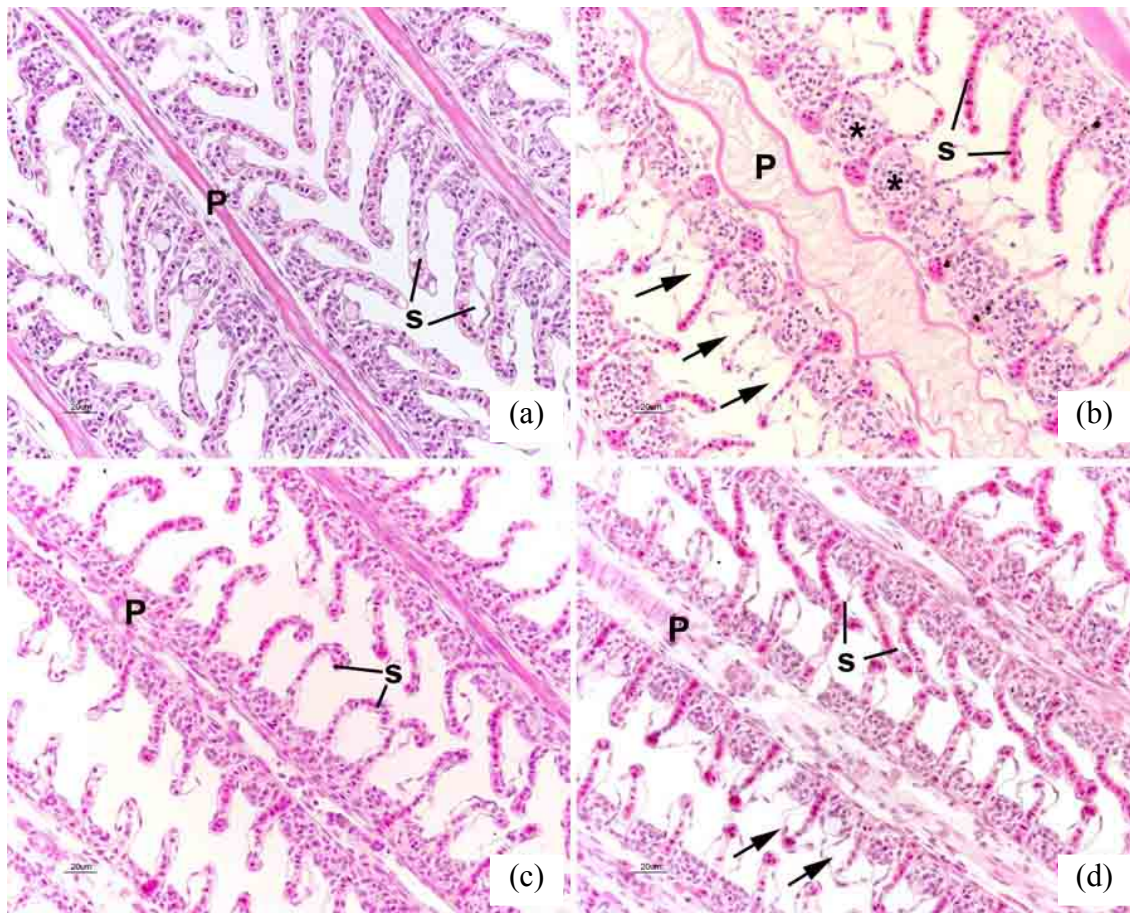


Figure 1 Gills of *O. niloticus* in group 1 (a) showing normal arrangement of primary (P) and secondary (s) lamellae; group 2 (b) showing edema or epithelial lifting (arrows) and hyperplasia (*); group 3 (c) no recognition change was observed; group 4 (d) showing similar alterations as (b), but less severe.

Table 1 Semiquantitative scoring of gill lesions in *O. niloticus* in each group^a.

Lesion	Group 1	Group 2	Group 3	Group 4
Edema or epithelial lifting	-	+++	-	++
Hyperplasia	-	+++	-	+

^a Score value: (-) none, (+) mild, (++) moderate, (+++) severe occurrence.

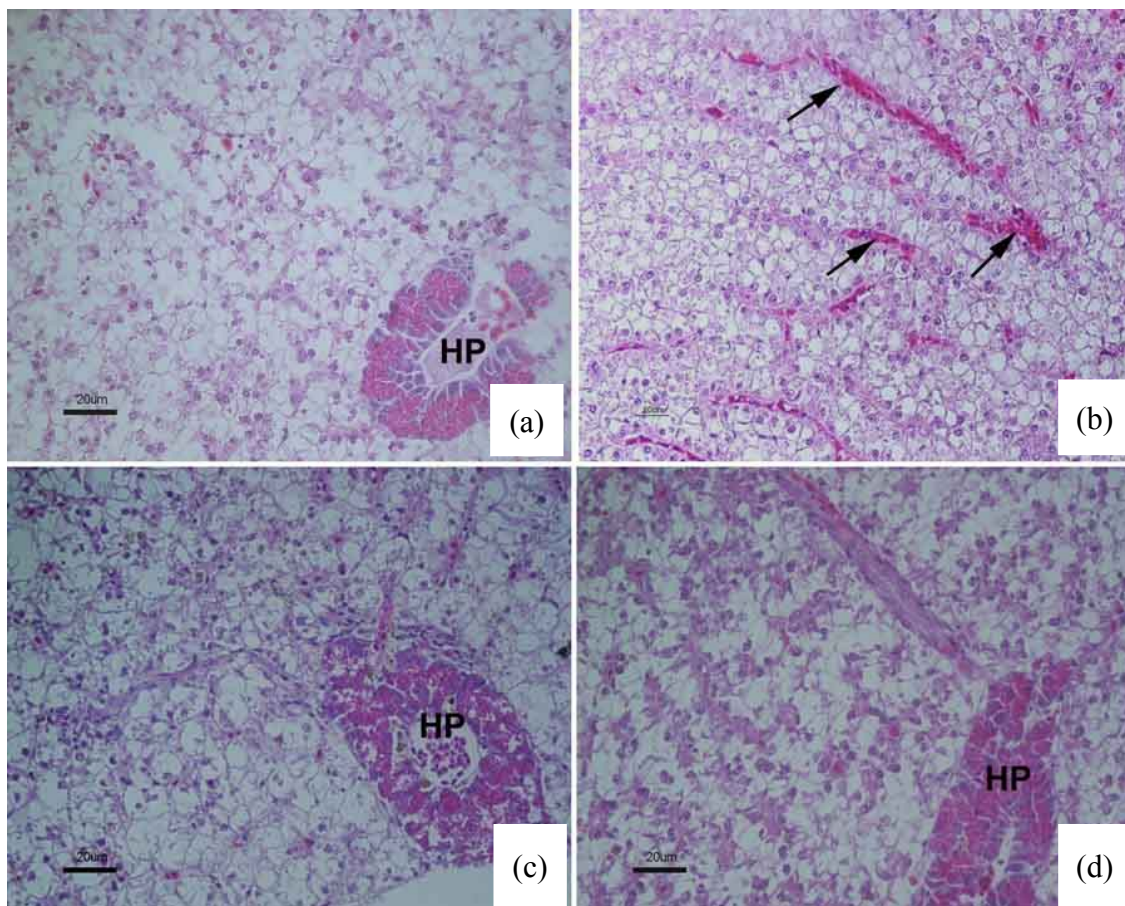


Figure 2 Liver of *O. niloticus* in group 1 (a) showing normal hepatocytes and blood sinusoids; group 2 (b) showing blood congestion (arrows) and vacuolization; group 3 (c) no recognition change was observed; group 4 (d) showing similar alterations as (b), but less severe. Note HP=Hepatopancreas.

Table 2 Semiquantitative scoring of liver lesions in *O. niloticus* in each group^a.

Lesion	Group 1	Group 2	Group 3	Group 4
Vacuolization	-	+++	-	++
Blood congestion	-	+++	-	++

^a Score value: (-) none, (+) mild, (++) moderate, (+++) severe occurrence.

Kidney

Control group: The kidney is a brown-long organ, extending the length of the body cavity. It is divided into 2 parts; an anterior that composed of hemopoietic elements, and a posterior. The nephron of the typical freshwater fish is composed of a well-vascularized glomerulus, renal tubules which are proximal, distal segments, and a collecting duct system. No recognizable changes were observed in the renal of G1 and G3 throughout this experiment (**Figures 3a, 3c**).

Treated groups: There was atrophy in some glomeruli and renal tubular necrosis in G2. Likewise, in the G4, similar alterations as those observed in G2 were displayed, but they were less severe. Moreover, a

few hemosiderin pigments accumulated in some areas (**Figures 3b, 3d**). The semiquantitative scoring of kidney lesions is shown in **Table 3**.

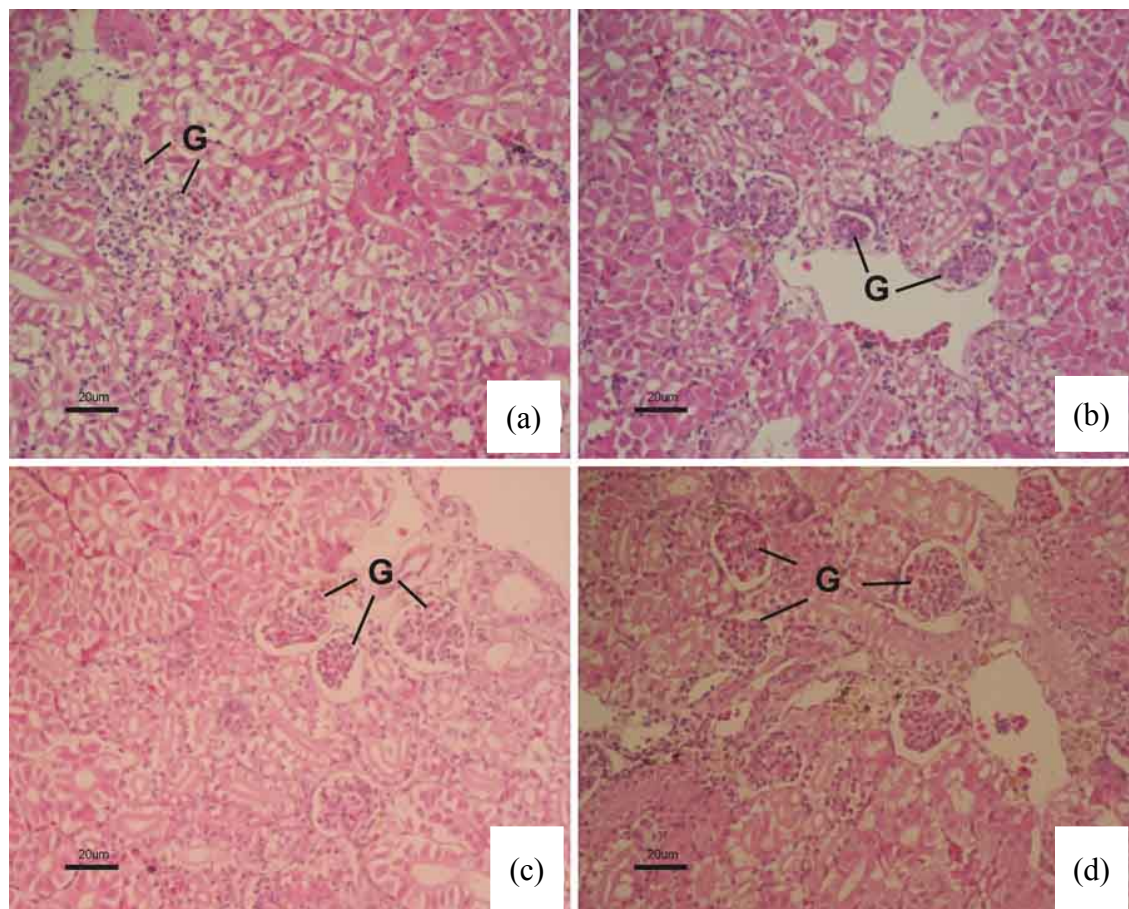


Figure 3 Kidney of *O. niloticus* in group 1 (a) showing normal appearance of glomerulus (G) and renal tubules; group 2 (b) showing glomerulus atrophy and necrosis in some areas; group 3 (c) no recognition change was observed; group 4 (d) showing similar alterations as (b), but less severe, and a few hemosiderin.

Table 3 Semiquantitative scoring of kidney lesions in *O. niloticus* in each group^a.

Lesion	Group 1	Group 2	Group 3	Group 4
Glomerulus atrophy	-	++	-	+
Renal tubular necrosis	-	+++	-	+
Hemosiderin accumulation	-	+	-	+

^a Score value: (-) none, (+) mild, (++) moderate, (+++) severe occurrence.

Intestine

Control group: The intestine is divided into (1) the anterior portion from the pyloric sphincter to the first loop posterior to the stomach as the pyloric intestine; (2) the coiled portion as the middle intestine, and (3) the posterior portion to the last loop as the rectal intestine. The intestine had simple columnar epithelium with scattered goblet cells. A thin lamina propria was part of the mucosa but was not clearly separated from the submucosa. The tall longitudinal folds, which often branched, projected into the lumen. The muscularis had inner circular and outer longitudinal layers of smooth muscle. The serosa was composed of a very thin layer of connective tissue covered by mesothelium. The mucosa of the intestine had tall columnar epithelium with a striated border and nuclei near the center of the cell. No recognizable changes were observed in the intestine of G1 and G3 throughout this experiment (**Figures 4a, 4c**).

Treated groups: The degeneration and necrosis of the longitudinal folds were seen in the Fe-NTA treatment group (G2). Moreover, hyperplasia and hypertrophy of goblet cells were also observed. No recognizable changes were observed in G4 (**Figures 4b, 4d**). The semiquantitative scoring of intestine lesions is shown in **Table 4**.

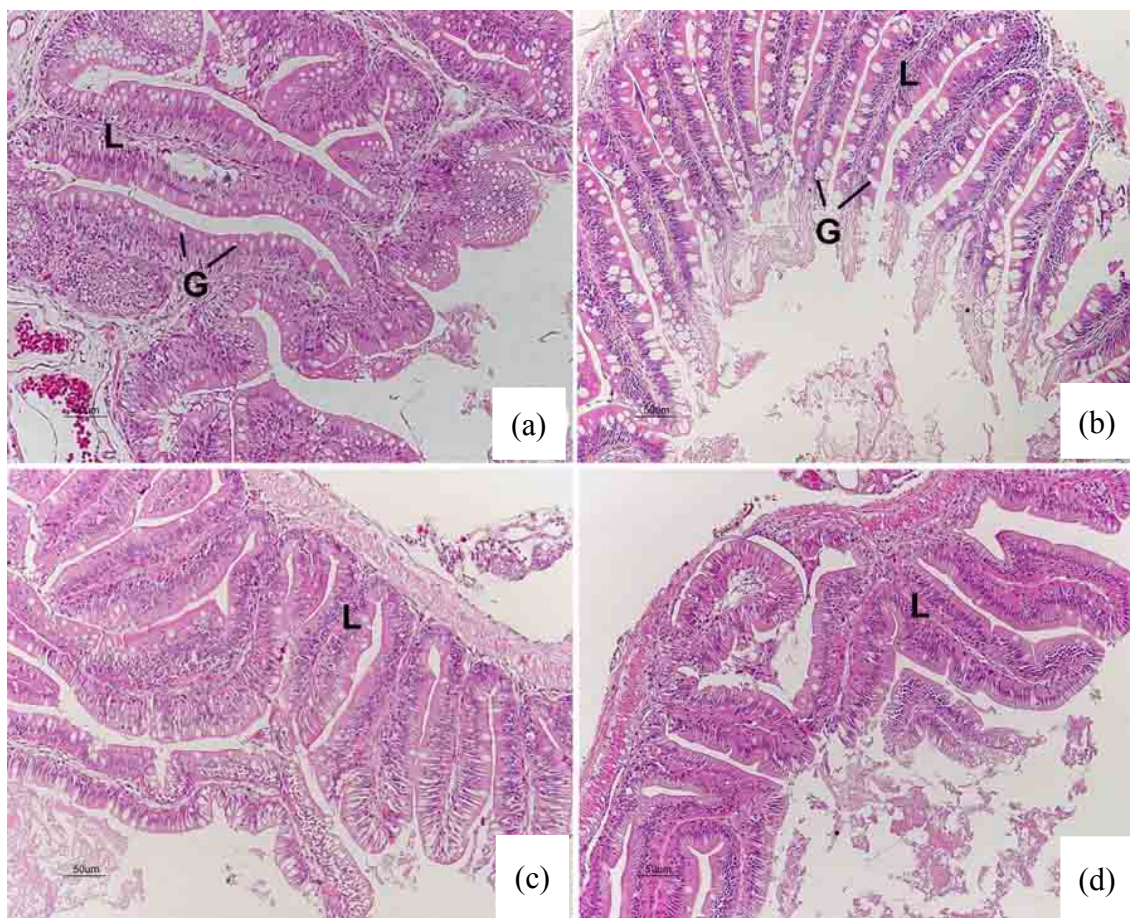


Figure 4 Intestine of *O. niloticus* in group 1 (a) showing normal appearance of simple columnar epithelium with scattered goblet cells (G) and tall longitudinal folds (L), which projected into the lumen; group 2 (b) showing degeneration and necrosis of longitudinal folds, hyperplasia, and hypertrophy of goblet cells; group 3 (c) and group 4 (d) no recognition change was observed.

Table 4 Semiquantitative scoring of intestine lesions in *O. niloticus* in each group^a.

Lesion	Group 1	Group 2	Group 3	Group 4
Hyperplasia and hypertrophy of goblet cell	-	+++	-	-
Necrosis	-	+++	-	-

^a Score value: (-) none, (+) mild, (++) moderate, (+++) severe occurrence.

Discussion

The present results suggest that pomegranate leaves have the ability to reduce lesions in fish tissue after Fe-NTA exposure. No recognition change was seen in the histopathological analysis of the tissues of the control group (G1) and PG feeding groups (G3). This result was similar to previous studies [30,31]. Patel *et al.* [31] reported that the oral administration of pomegranate extract for 90 days at levels up to 600 mg kg⁻¹ day⁻¹ did not cause adverse effects in male and female rats in clinical observation, ophthalmic examinations, body weight gains, feed consumption, clinical pathology evaluations, hematology, serum chemistry parameters and organ weight. Our study investigated the efficiency of pomegranate leaf diet supplement in reducing allied damage in vivo by Fe-NTA toxicity. Food dosed with this supplement significantly inhibited Fe-NTA, inducing histopathological changes in fish tissue. These obtained results agreed with our previous studies in the protective influence of *Psidium guajava*, reducing ferric nitrilotriacetate toxicity in *Puntius altus* [32], ascorbic acid against the toxicity of waterborne cadmium exposure in *P. altus* [33] and lead exposure in *O. niloticus* [34]. Intraperitoneally injected Fe-NTA was absorbed into the portal vein through the mesothelium and passed into the circulation via the liver [35]. The present study demonstrated that a single injection of Fe-NTA caused histopathological alterations in the kidney, gills, liver, and intestines. Histopathological alteration, i.e., atrophy of glomerulus, tubular swelling, and necrosis, were found in the renal tissue. Edema, lamellar cell hyperplasia, epithelial lifting, lamellar fusion, and aneurysm were seen in the gills. There was blood congestion in the sinusoids, vacuolization, and necrosis in the hepatocytes. Recent studies have shown the variety of changes in the liver of the experimental animal resulting from exposure to Fe-NTA [22,36]. However, fish fed with PG (G4) in the present study showed slight alterations when compared with the Fe-NTA without PG feeding group (G2). The outcomes of the present study are in agreement with the study of Kaur *et al.* [22] who reported that the histopathological changes in the livers of mice produced by Fe-NTA, such as ballooning degeneration, fatty changes, hemorrhage, and necrosis were also alleviated by the 150 mg kg⁻¹ pomegranate flower extract. In additional, the efficiency of PG was studied in the inhibition of gastric mucosal injury i.e., protection to erosion of gastric mucosa, sub-mucosa edema, and neutrophil infiltration [37]. Ajaikumar and colleague [37] reported that plants, which contain alkaloids, flavonoids, and polyphenols, have several biological properties, including protective effects through several mechanisms, such as antioxidant effects. The chemical content in each part of a pomegranate, such as seed oil, consists of 80 % conjugated octadecatrienoic fatty acid, with a high content of *cis* 9, *trans* 11, *cis* 13 acid. The juice has anthocyanin, which is a potent antioxidant. Pericarp includes peel, rind, and hull, which have both flavonoids and tannins. Leaves also contain glycosides of apigenin and flavone with progestinic and anxiolytic properties [13]. Therefore, the protective effect of PG may be due to the presence of these compounds.

Conclusions

In conclusion, we can say that, a dietary supplement of *Punica granatum* leaf is effective in reducing ferric nitrilotriacetate toxicity in fish via histopathological study. Thus, our data suggest that pomegranate extract may be a new dietary supplement for aquaculture. However, the limited study in its mechanism means that further work is required for the isolation and characterization of the individual compounds present in pomegranate extract, and to determine the mechanisms involved in the protective effect of pomegranate extract.

Acknowledgements

The authors are thankful to Mr. Somnuk Guta for his technical assistance. The authors are also thankful to the Fish Research Unit, Department of Pathobiology, Faculty of Science, Mahidol University, Bangkok, for the technical support of their laboratory. This study was funded by the Thailand Research Fund and the Commission on Higher Education: Research Grant for Mid-Career University Faculty (RMU5180001), and in part by the Graduate Studies of Mahidol University Alumni Association.

References

- [1] S Naz, R Siddiqi, S Ahmad, SA Rasool and SA Sayeed. Antibacterial activity directed isolation of compounds from *Punica granatum*. *J. Food Sci.* 2007; **72**, 341-5.
- [2] M Mekni, G Flamini, M Garrab, RB Hmida, I Cheraief, M Mastouri and M Hammami. Aroma volatile components, fatty acids and antibacterial activity of four Tunisian *Punica granatum* L. flower cultivars. *Ind. Crop. Prod.* 2013; **48**, 111-7.
- [3] SS Dahham, MN Ali, H Tabassum and M Khan. Studies on antibacterial and antifungal activity of pomegranate (*Punica granatum* L.). *Am. Eurasian J. Agric. Environ. Sci.* 2010; **9**, 273-81.
- [4] A Mansourian, N Boojarpour, S Ashnagar, JM Beitollahi and AR Shamshiri. The comparative study of antifungal activity of *Syzygium aromaticum*, *Punica granatum* and nystatin on *Candida albicans*; An *in vitro* study. *J. Med. Mycol.* 2014; **24**, e163-8.
- [5] T Ismail, P Sestili and S Akhtar. Pomegranate peel and fruit extracts: A review of potential anti-inflammatory and anti-infective effects. *J. Ethnopharmacol.* 2012; **143**, 397-405.
- [6] NT Hai, NV Thanh, BT Tho and M Atsushi. A study about anthelmintic effect of *Punica granatum* L bark on veterinary endoparasites. *Asian J. Pharmacut. Clin. Res.* 2014; **7**, 148-52.
- [7] CP Forest, H Padma-Nathan and HR Liker. Efficacy and safety of pomegranate juice on improvement of erectile dysfunction in male patients with mild to moderate erectile dysfunction: a randomized, placebo-controlled, double-blind, crossover study. *Int. J. Impot. Res.* 2007; **19**, 564-7.
- [8] M Cam, Y Hisil and G Durmaz. Classification of eight pomegranate juices based on antioxidant capacity measured by four methods. *Food Chem.* 2009; **112**, 721-6.
- [9] J Bekir, M Mars, JP Soucard and J Bouajila. Assessment of antioxidant, anti-inflammatory, anti-cholinesterase and cytotoxic activities of pomegranate (*Punica granatum*) leaves. *Food Chem. Toxicol.* 2013; **55**, 470-5.
- [10] P Bagri, M Ali, V Aeri, M Bhowmik and S Sultana. Antidiabetic effect of *Punica granatum* flowers: Effect on hyperlipidemia, pancreatic cells lipid peroxidation and antioxidant enzymes in experimental diabetes. *Food Chem. Toxicol.* 2009; **47**, 50-4.
- [11] AN Patel, DD Bandawane and NK Mhetre. Pomegranate (*Punica granatum* Linn.) leaves attenuate disturbed glucose homeostasis and hyperglycemia mediated hyperlipidemia and oxidative stress in streptozotocin induced diabetic rats. *Eur. J. Integr. Med.* 2014; **6**, 307-21.
- [12] MM Joseph, SR Aavind, SK George, S Varghese and TT Sreelekha. A galactomannan polysaccharide from *Punica granatum* imparts *in vitro* and *in vivo* anticancer activity. *Carbohydr. Polym.* 2013; **98**, 1466-75.
- [13] S Sudheesh and NR Vijayalakshmi. Flavonoids from *Punica granatum*-potential antiperoxidative agents. *Fitoterapia* 2005; **76**, 181-6.

- [14] EP Lansky and RA Newman. *Punica granatum* (pomegranate) and its potential for prevention and treatment of inflammation and cancer. *J. Ethnopharmacol.* 2007; **109**, 177-206.
- [15] Sakai M. Current research status of fish immunostimulants. *Aquaculture* 1999; **172**, 63-92.
- [16] M Reverter, N Bontemps, D Lecchini, B Banaigs and P Sasal. Use of plant extracts in fish aquaculture as an alternative to chemotherapy: Current status and future perspectives. *Aquaculture* 2014; **433**, 50-61.
- [17] RL Anderson, WE Bishop and RL Campbell. A review of the environment and mammalian toxicology of nitrilotriacetic acid. *Crit. Rev. Toxicol.* 1985; **15**, 1-102.
- [18] KD Oakes, LM Hewitt, ME McMaster, C Wood, KR Munkittrick and GJ Van Der Kraak. Oxidative stress and sex steroid levels in fish following short-term exposure to pulp-mill effluents. *J. Toxicol. Environ. Health* 2005; **68**, 267-86.
- [19] M Awai, M Narasaki, Y Yamanoi and S Seno. Induction of diabetes in animals by parenteral administration of ferric nitrilotriacetate. A model of experimental hemochromatosis. *Am. J. Pathol.* 1979; **95**, 663-72.
- [20] D Singh, V Chander and K Chopra. Protective effect of naringin, a bioflavonoid on ferric nitrilotriacetate-induced oxidative renal damage in rat kidney. *Toxicol.* 2004; **201**, 1-8.
- [21] S Ansar and M Iqbal. Role of ascorbic acid in counteracting ferric nitrilotriacetate (Fe-NTA)-induced nephrotoxicity in rats. *Pharm. Biol.* 2013; **51**, 1559-63.
- [22] G Kaur, Z Jabbar, M Athar and MS Alam. *Punica granatum* (pomegranate) flower extract possesses potent antioxidant activity and abrogates Fe-NTA induced hepatotoxicity in mice. *Food Chem. Toxicol.* 2006; **44**, 984-93.
- [23] S Ansar, H Tabassum and N Jameil. Protective effect of butylated hydroxytoluene on ferric nitrilotriacetate induced hepatotoxicity and oxidative stress in mice. *Hum. Exp. Toxicol.* 2013; **32**, 513-21.
- [24] M Liu, S Okada and T Kawabata. Radical promoting free iron level in the serum of rats treated with ferric nitrilotriacetate, comparison with iron chelate complexes. *Acta Medica Okayama* 1991; **45**, 401-8.
- [25] M Iqbal, U Giri and M Athar. Ferric nitrilotriacetate (Fe-NTA) is a potent hepatic tumor promoter and acts through the generation of oxidative stress. *Biochem. Biophys. Res. Commun.* 1995; **212**, 557-63.
- [26] American Public Health Association (APHA). *Standard methods for the examination of water and wastewater*. 21sted. The American Public Health Association, American Water Works Association, and Water Pollution Control Federation, Washington DC, 2005.
- [27] EU Winkaler, TRM Santos, JG Machado-Neto and CBR Martinez. Acute lethal and sublethal effects of neem leaf extract on the neotropical freshwater fish *Prochilodus lineatus*. *Comp. Biochem. Physiol.* 2007; **145**, 236-44.
- [28] GL Humason. *Animal tissue techniques*. 3rd ed. W.H. Freeman and Company, San Francisco, 1972.
- [29] J Schwaiger, R Wanke, S Adam, M Pawert, W Honnen and R Triebkorn. The use of histopathological indicators to evaluate contaminant-related stress in fish. *J. Aquat. Ecosyst. Stress Recovery* 1997; **6**, 75-86.
- [30] B Cerda, JJ Ceron, FA Tomas-Barberan and JC Espin. Repeated oral administration of high doses of pomegranate ellagitannin punicalagin to rats for 37 days is not toxic. *J. Agric. Food Chem.* 2003; **51**, 3493-501.
- [31] C Patel, P Dadhaniya, L Hingorani and MG Soni. Safety assessment of pomegranate fruit extract: Acute and subchronic toxicity studies. *J. Food Sci.* 2008; **46**, 2728-35.
- [32] W Jiraungkoorskul, R Singhakumar, K Jiraungkoorskul and P Kosai. Dietary *Psidium guajava* supplementation reducing ferric nitrilotriacetate toxicity in *Puntius altus*. *Res. J. Med. Plant* 2011; **5**, 764-71.
- [33] W Jiraungkoorskul, S Sahaphong, N Kangwanrangsang and K Myung-Huk. Histopathological study: The effect of ascorbic acid on cadmium exposure in fish (*Puntius altus*). *J. Fish Aquat. Sci.* 2006; **1**, 191-9.

- [34] W Jiraungkoorskul, S Sahaphong, N Kangwanrangsang and S Zakaria. The protective influence of ascorbic acid against the genotoxicity of waterborne lead exposure in Nile tilapia (*Oreochromis niloticus*). *J. Fish Biol.* 2008; **73**, 355-66.
- [35] TY Umemura, K Sai, A Takagi, R Hasegawa and Y Kurakawa. Oxidative DNA damage lipid peroxidation and nephrotoxicity induced in the rat kidney after ferric nitrilotriacetate administration. *Cancer Lett.* 1990; **54**, 95-100.
- [36] I Celik, A Temur and I Isik. Hepatoprotective role and antioxidant capacity of pomegranate (*Punica granatum*) flowers infusion against trichloroacetic acid-exposed in rats. *Food Chem. Toxicol.* 2009; **47**, 145-9.
- [37] KB Ajaikumar, M Asheef, BH Babu and J Padikkala. The inhibition of gastric mucosal injury by *Punica granatum* L. (pomegranate) methanolic extract. *J. Ethnopharmacol.* 2005; **96**, 171-6.